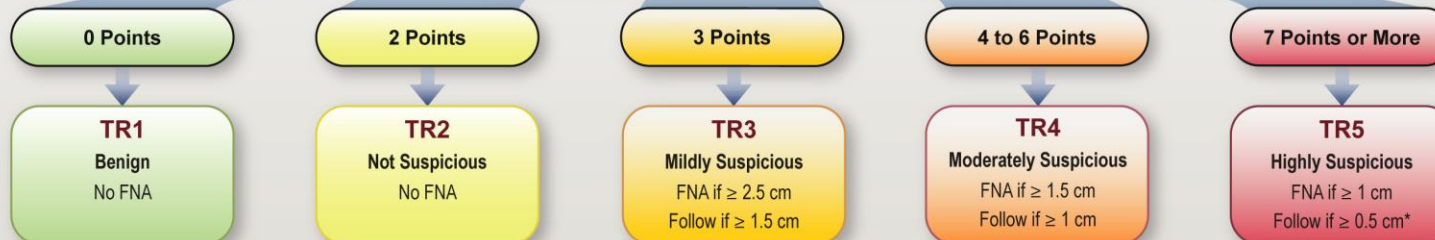


ACR TI-RADS

COMPOSITION (Choose 1)		ECHOGENICITY (Choose 1)		SHAPE (Choose 1)		MARGIN (Choose 1)		ECHOGENIC FOCI (Choose All That Apply)	
Cystic or almost completely cystic	0 points	Anechoic	0 points	Wider-than-tall	0 points	Smooth	0 points	None or large comet-tail artifacts	0 points
Spongiform	0 points	Hyperechoic or isoechoic	1 point	Taller-than-wide	3 points	Ill-defined	0 points	Macrocalcifications	1 point
Mixed cystic and solid	1 point	Hypoechoic	2 points			Lobulated or irregular	2 points	Peripheral (rim) calcifications	2 points
Solid or almost completely solid	2 points	Very hypoechoic	3 points			Extra-thyroidal extension	3 points	Punctate echogenic foci	3 points

Add Points From All Categories to Determine TI-RADS Level



COMPOSITION	ECHOGENICITY	SHAPE	MARGIN	ECHOGENIC FOCI
<p><i>Spongiform</i>: Composed predominantly (>50%) of small cystic spaces. Do not add further points for other categories.</p> <p><i>Mixed cystic and solid</i>: Assign points for predominant solid component.</p> <p>Assign 2 points if composition cannot be determined because of calcification.</p>	<p><i>Anechoic</i>: Applies to cystic or almost completely cystic nodules.</p> <p><i>Hyperechoic/isoechoic/hypoechoic</i>: Compared to adjacent parenchyma.</p> <p><i>Very hypoechoic</i>: More hypoechoic than strap muscles.</p> <p>Assign 1 point if echogenicity cannot be determined.</p>	<p><i>Taller-than-wide</i>: Should be assessed on a transverse image with measurements parallel to sound beam for height and perpendicular to sound beam for width.</p> <p>This can usually be assessed by visual inspection.</p>	<p><i>Lobulated</i>: Protrusions into adjacent tissue.</p> <p><i>Irregular</i>: Jagged, spiculated, or sharp angles.</p> <p><i>Extrathyroidal extension</i>: Obvious invasion = malignancy.</p> <p>Assign 0 points if margin cannot be determined.</p>	<p><i>Large comet-tail artifacts</i>: V-shaped, >1 mm, in cystic components.</p> <p><i>Macrocalcifications</i>: Cause acoustic shadowing.</p> <p><i>Peripheral</i>: Complete or incomplete along margin.</p> <p><i>Punctate echogenic foci</i>: May have small comet-tail artifacts.</p>

*Refer to discussion of papillary microcarcinomas for 5-9 mm TR5 nodules.