

Thyroid Ultrasound Reporting Lexicon: White Paper of the ACR Thyroid Imaging, Reporting and Data System (TIRADS) Committee

Edward G. Grant, MD^a, Franklin N. Tessler, MD^b, Jenny K. Hoang, MBBS^c, Jill E. Langer, MD^d, Michael D. Beland, MD^e, Lincoln L. Berland, MD^b, John J. Cronan, MD^e, Terry S. Desser, MD^f, Mary C. Frates, MD^g, Ulrike M. Hamper, MD^b, William D. Middleton, MDⁱ, Carl C. Reading, MD^j, Leslie M. Scoutt, MD^k, A. Thomas Stavros, MD^l, Sharlene A. Teefey, MDⁱ

Abstract

Ultrasound is the most commonly used imaging technique for the evaluation of thyroid nodules. Sonographic findings are often not specific, and definitive diagnosis is usually made through fine-needle aspiration biopsy or even surgery. In reviewing the literature, terms used to describe nodules are often poorly defined and inconsistently applied. Several authors have recently described a standardized risk stratification system called the Thyroid Imaging, Reporting and Data System (TIRADS), modeled on the BI-RADS system for breast imaging. However, most of these TIRADS classifications have come from individual institutions, and none has been widely adopted in the United States. Under the auspices of the ACR, a committee was organized to develop TIRADS. The eventual goal is to provide practitioners with evidence-based recommendations for the management of thyroid nodules on the basis of a set of well-defined sonographic features or terms that can be applied to every lesion. Terms were chosen on the basis of demonstration of consistency with regard to performance in the diagnosis of thyroid cancer or, conversely, classifying a nodule as benign and avoiding follow-up. The initial portion of this project was aimed at standardizing the diagnostic approach to thyroid nodules with regard to terminology through the development of a lexicon. This white paper describes the consensus process and the resultant lexicon.

Key Words: Thyroid nodule, ultrasound, thyroid cancer, structured reporting, thyroid imaging

J Am Coll Radiol 2015;12:1272-1279. Copyright © 2015 American College of Radiology

INTRODUCTION

The incidence of thyroid nodules has increased tremendously in recent years. The reasons for this increase are likely multifactorial but are largely attributed to widespread application of high-resolution ultrasound to the thyroid itself and the frequent incidental detection of nodules on

other imaging modalities. In distinction to palpation, which demonstrates nodules in only 5% to 10% of the population, autopsy and sonography detect them in at least 60% [1]. Although nodules are extremely common, the incidence of malignancy in them is relatively low, ranging between 1.6% and 12% [2,3].

^aKeck School of Medicine, University of Southern California, Los Angeles, California.

^bUniversity of Alabama at Birmingham, Birmingham, Alabama.

^cDuke University School of Medicine, Durham, North Carolina.

^dUniversity of Pennsylvania, Philadelphia, Pennsylvania.

^eBrown University, Providence, Rhode Island.

^fStanford University Medical Center, Stanford, California.

^gBrigham and Women's Hospital, Boston, Massachusetts.

^hJohns Hopkins University, School of Medicine, Baltimore, Maryland.

ⁱWashington University School of Medicine, St. Louis, Missouri.

^jMayo Clinic College of Medicine, Rochester, Minnesota.

^kYale University, New Haven, Connecticut.

^lSutter Medical Group, Englewood, Colorado.

Corresponding author and reprints: Edward G. Grant, MD, Keck School of Medicine, University of Southern California, Department of Radiology, 1500 San Pablo Street, Los Angeles, CA 90033; e-mail: edgrant@med.usc.edu.

The authors have no conflicts of interest related to the material discussed in this article.

Ultrasound is superior to other modalities in characterizing thyroid nodules. Unfortunately, the findings are often not specific, and definitive diagnosis usually requires fine-needle aspiration (FNA) biopsy or even surgery. Because nodules are so common, a significant burden is placed on the health care system, and considerable anxiety may occur in patients. Furthermore, the majority of thyroid cancers are of the papillary type, which is typically indolent. Long-term studies by Ito et al [4] showed no difference in outcomes between patients with biopsy-proven carcinomas <1 cm undergoing thyroidectomy and those followed with no surgical intervention.

The literature regarding thyroid nodule characterization with ultrasound is expansive, and several professional organizations have put forth position or consensus statements. The two best known in the United States are from the American Thyroid Association (ATA) and the Society of Radiologists in Ultrasound [5,6]. Because FNA biopsy is such an integral part of the workup of thyroid nodules, the American Society of Cytopathology convened its own consensus panel to standardize reporting of biopsy results, which is known as the Bethesda classification [7].

Several authors have suggested a standardized risk stratification system called the Thyroid Imaging, Reporting and Data System (TIRADS), modeled on the BI-RADS[®] system for breast imaging, which has received widespread acceptance [8-10]. These proposals include the initial report by Horvath et al [9], as well as subsequent proposals by Kwak et al [8] and Park et al [10]. Despite these efforts, none of these TIRADS classifications have been widely adopted, particularly in the United States.

Our objective, therefore, was to develop a practical, standard lexicon for describing the sonographic characteristics of thyroid nodules, with the ultimate aim of applying it to risk stratification and triage of nodules for consistent follow-up in clinical practice.

METHODS

Beginning in 2012, a group of radiologists with expertise in thyroid imaging undertook a three-stage process under the auspices of the ACR; a subcommittee was charged with completing each one. The first effort, led by Lincoln Berland, MD, and Jenny Hoang, MBBS, was aimed at proposing recommendations for nodules discovered incidentally on imaging. This work led to a white paper published in 2015 [11]. The work reported here on the development of an ultrasound

lexicon was led by Edward Grant, MD, whereas the final stage, which will be directed at risk stratification on the basis of the lexicon, will be led by Franklin Tessler, MD.

After an extensive literature review, relevant articles were distributed to all subcommittee members. Each radiologist was assigned three or four articles and was asked to list terms used by the authors to describe thyroid nodules. ACR staff members collated the lists, and a master list was drawn up. Frequency of use was the initial guide for determining which terms would be included in the lexicon.

The committee initially identified nine categories or families of terms that could be applied to all thyroid nodules: nodule composition, echogenicity, characteristics of cystic/solid components, shape, size/dimensions, margins, halo, echogenic foci, and flow/Doppler. Next, subcommittee members re-reviewed the literature to determine whether there was evidence that the categories and terms had discriminatory value in distinguishing benign from malignant nodules, which led to culling the category list. This process resulted in the selection of six final categories. Several of the original categories as well as numerous terms were eliminated from the lexicon or incorporated into other groups based either on infrequency of use or lack of statistical agreement with regard to their diagnostic value. Two members were assigned to develop definitions for each category and its individual terms in a format used for other ACR "RADS" lexicons.

THYROID ULTRASOUND CATEGORIES

Category 1: Composition

Definition.

- Composition describes the internal components of a nodule, that is, the presence of soft tissue or fluid, and the proportion of each.
 - Solid: Composed entirely or nearly entirely of soft tissue, with only a few tiny cystic spaces (Fig. 1A).
 - Predominately solid: Composed of soft tissue components occupying 50% or more of the volume of the nodule (Fig. 1B, online only).
 - Predominately cystic: Composed of soft tissue components occupying less than 50% of the volume of the nodule (Fig. 1C, online only).
 - Cystic: Entirely fluid filled.

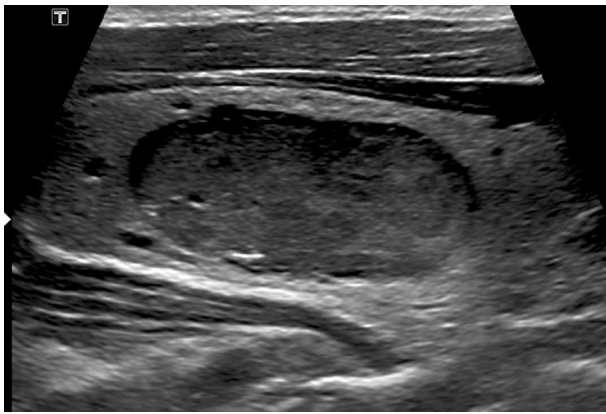

Fig 1A. Composition. (A) Solid nodule: 46-year-old man with 3.5-cm solid, hypoechoic nodule. Margins are smooth. Macrocalcifications were identified on other sections. Diagnosis: medullary carcinoma. [Figures 1B to 1D](#) available online.

- Spongiform: Composed predominately of tiny cystic spaces ([Fig. 1D](#), online only).

Background and Significance.

- A nodule should fit into one of the foregoing five categories. However, rarely, it may be difficult to determine if a nodule is filled with hemorrhagic material or is solid. Color Doppler flow may be useful in differentiating between the two.
- Papillary thyroid carcinoma (PTC) is most commonly solid, but many solid nodules are also benign; a solid nodule has a 15% to 27% chance of being malignant [6]. Some nodules undergo cystic degeneration or necrosis. A recent study of partially cystic nodules showed that the prevalence of malignancy was low whether the nodule was predominately cystic (6.1%) or predominately solid (5.7%) [12]. When evaluating a partially cystic nodule, it is important to evaluate the solid component. If the solid component is eccentrically (peripherally) located within a partially cystic nodule and the margin of the solid component has an acute angle with the wall of the nodule, the risk for malignancy is increased. Furthermore, if the solid component is hypoechoic, is lobulated, has an irregular border or punctate echogenic foci line, or has vascular flow, the risk for malignancy is increased. If the solid component is isoechoic, is centrally located within the nodule or, if peripheral, has no acute angle with the nodule wall, or has a smooth margin, spongiform appearance, or comet tail artifacts, it is likely benign [13,14].
- Purely cystic nodules or spongiform nodules have a very low risk for malignancy [6]. Two definitions of

spongiform nodules have been proposed in the literature. When a spongiform nodule was defined as “the aggregation of multiple microcystic components in more than 50% of the volume of the nodule,” only one in 52 spongiform nodules was malignant [15]. When a spongiform nodule was defined as tiny cystic spaces involving the entire nodule, all 210 spongiform nodules were benign on FNA biopsy [16].

Comment.

- Terms used to describe partially cystic or partially solid nodules vary, with some authors breaking down the ratio of the two into numerical values on the basis of percentage whereas others choose to be more descriptive. The committee believed that the simple, subjective description of predominately cystic versus predominately solid would suffice.
- Although somewhat controversial, the committee agreed that finding several tiny cystic spaces in an otherwise completely solid nodule would still allow it to be classified as solid.

Category 2: Echogenicity

Definition.

- Level of echogenicity of the solid, noncalcified component of a nodule, relative to surrounding thyroid tissue [8,10,15,17-19].
 - Hyperechoic: Increased echogenicity relative to thyroid tissue ([Fig. 2A](#), online only).
 - Isoechoic: Similar echogenicity relative to thyroid tissue.
 - Hypoechoic: Decreased echogenicity relative to thyroid tissue ([Fig. 2B](#), online only).
 - Very hypoechoic: Decreased echogenicity relative to adjacent neck musculature ([Fig. 2C](#)).

Background and Significance.

- The level of nodule echogenicity is associated with both benign and malignant lesions. Very hypoechoic nodules have low sensitivity but very high specificity. Hypoechoic is more sensitive but does not have high specificity [15,18,19].

Comment.

- The echogenicity of the solid component of a nodule should be compared with normal-appearing thyroid tissue, usually immediately adjacent to the nodule. In the setting of background abnormal thyroid tissue echogenicity, such as in Hashimoto’s thyroiditis, the echogenicity of the solid component should still be

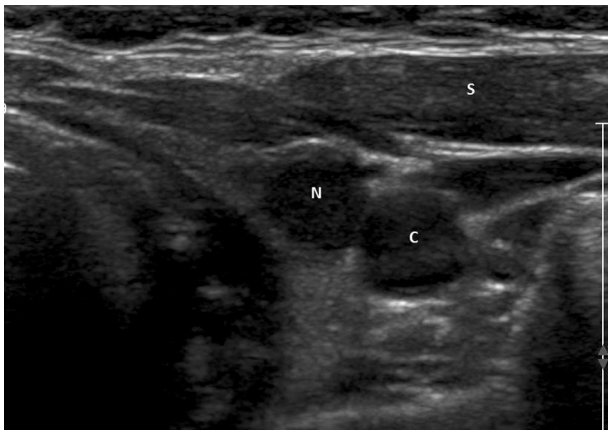


Fig 2C. Echogenicity. Very hypoechoic nodule: 55-year-old woman with 1.0-cm very hypoechoic left lobe nodule (N). Margins are smooth. Note that nodule is less echogenic than adjacent strap muscles (S) and essentially isoechoic to the common carotid artery (C). Diagnosis: papillary carcinoma. Figures 2A and 2B available online.

described relative to the adjacent thyroid tissue, but it may be noted that the background tissue is of altered echogenicity.

- If the nodule is of mixed echogenicity, it can be described as “predominantly” hyperechoic, isoechoic, or hypoechoic.

Category 3: Shape

Term: taller-than-wide.

Definition.

- A taller-than-wide shape is defined as a ratio of >1 in the anteroposterior diameter to the horizontal diameter when measured in the transverse plane (Fig. 3).

Background and Significance.

- Taller-than-wide shape is a major feature for the categorization of thyroid nodules that are suspicious or suggestive of malignancy. The corresponding pathologic feature leading to this appearance is thought to be decreased compressibility. This finding is seen in 12% of thyroid nodules [8]. Sensitivity ranges between 40% and 68%, specificity between 82% and 93%, positive predictive value between 0.58 and 0.73, and negative predictive value between 0.77 and 0.88 [8,17,20-22].

Comment.

- In studies that specify how measurements are made, there are no significant differences comparing transverse or longitudinal dimensions [20,23]. For simplicity and consistency, the committee chose the ratio of >1 in the

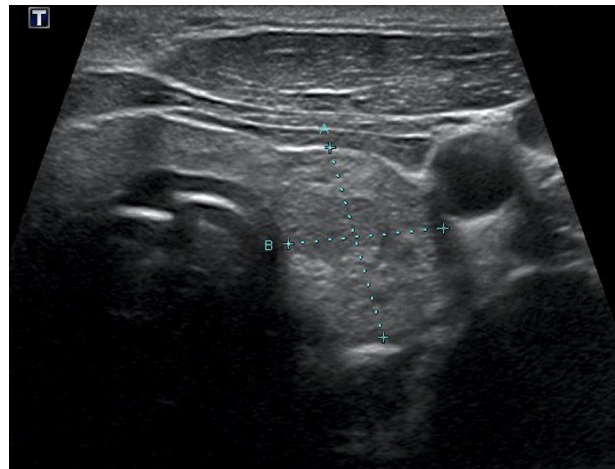


Fig 3. Shape: 56-year-old woman with taller-than-wide nodule in left lobe of thyroid. Dimensions measured in the transverse plane are 1.4 cm transverse \times 1.8 cm anteroposterior. Diagnosis: follicular variant, papillary carcinoma.

anteroposterior diameter to the horizontal diameter in the transverse plane.

Category 4: Size

How the nodule should be measured:

- Use maximal diameter on the basis of longitudinal, anteroposterior, and transverse measurements in centimeters per millimeter.

Background and Significance.

- Multiple studies have suggested that nodule size is not an independent predictor of malignancy risk in PTC. Tiny nodules can harbor malignancy, and large nodules are often benign. In a Finnish autopsy study of 101 thyroid glands, investigators found small, occult thyroid cancers in 36% [24]. As noted previously, the study by Ito et al [4] showed no value in performing thyroidectomy on small cancers.
- The correlation between nodule size and risk for malignancy remains controversial for nodules >1 cm. A 2013 study that included 7,346 nodules examined the effect of nodule size on the prevalence of thyroid cancer. At a threshold of 2 cm, the investigators found a statistically significant increase in cancer rate: 10.5% among the nodules 1 to 1.9 cm in diameter versus 15% for nodules >2 cm. Whether this is clinically significant is doubtful. In this study, larger nodules, when cancerous, were significantly more likely to have a histology other than papillary carcinoma (follicular, Hurthle cell, or other rare malignancies) [25].

Comment.

- Current thinking about biopsy of nodules <1 cm seems to be shifting to a more conservative approach. The most recent ATA guidelines [26] do not recommend biopsy of most lesions <1 cm. For nodules larger than 1 cm, considering the uncertainty between nodule size and malignancy risk, compared with the more consistent data on the impact of other sonographic features, we believe it is reasonable not to include size in the TIRADS scoring system.

Category 5: Margins

Definition.

- Refers to the border or interface between the nodule and the adjacent thyroid parenchyma or adjacent extrathyroidal structures.
 - Smooth: Uninterrupted, well-defined, curvilinear edge typically forming a spherical or elliptical shape (Fig. 4A, online only)
 - Irregular margin: The outer border of the nodule is spiculated, jagged, or with sharp angles with or without clear soft tissue protrusions into the parenchyma. The protrusions may vary in size and conspicuity and may be present in only one portion of the nodule (Fig. 4B).
 - Lobulated: Border has focal rounded soft tissue protrusions that extend into the adjacent parenchyma. The lobulations may be single or multiple and may vary in conspicuity and size (small lobulations are referred to as microlobulated) (Fig. 4C, online only).
 - Ill-defined: Border of the nodule is difficult to distinguish from thyroid parenchyma; the nodule lacks irregular or lobulated margins.
 - Halo: Border consists of a dark rim around the periphery of the nodule. The halo can be described as completely or partially encircling the nodule. In the literature, halos have been further characterized as uniformly thin, uniformly thick, or irregular in thickness.
 - Extrathyroidal extension: Nodule extends through the thyroid capsule (Fig. 4D, online only).

Background and Significance.

- A smooth border is more common in benign nodules, but between 33% and 93% of malignancies may have smooth borders [15,27]. Irregular and lobulated margins are features suspicious for thyroid malignancy [28]. These borders are

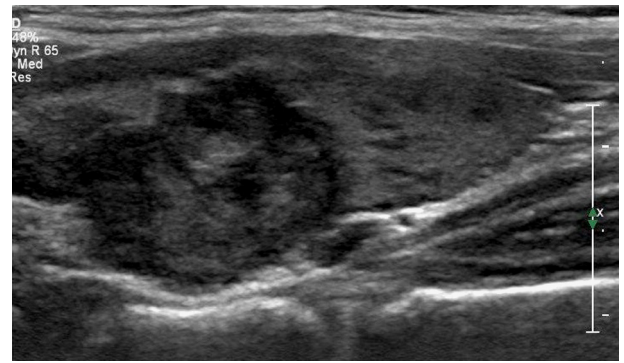


Fig 4B. Irregular margin: 47-year-old woman with heterogeneously hyperechoic 16-mm nodule with irregular margins. Note angulated borders anteriorly. Diagnosis: papillary carcinoma. Figures 4A, 4C, 4D available online.

considered to represent an aggressive growth pattern, although regions of thyroiditis can also have irregular margins. An ill-defined thyroid nodule margin has not been shown to be statically significantly associated with malignancy and is a common finding in benign hyperplastic nodules and thyroiditis [15,27,29].

- A halo may be due to a true fibrous capsule or a pseudocapsule. A uniform halo suggests a benign nodule because most thyroid malignancies are unencapsulated. However, a complete or incomplete halo has been noted in 10% to 24% of thyroid carcinomas.
- Extension of the nodule through the thyroid capsule into the adjacent soft tissue structures indicates invasive malignancy [29].

Comment.

- Analysis of the literature about the reported sensitivity and specificity of margin features is challenging because of previous nonuniformity in the definitions and the high rate of interobserver variability [15].

Category 6: Echogenic Foci

Definition.

- Refers to focal regions of markedly increased echogenicity within a nodule relative to the surrounding tissue. Echogenic foci vary in size and shape and may be encountered alone or in association with several well-known posterior acoustic artifacts.
 - Punctate echogenic foci: “Dot-like” foci having no posterior acoustic posterior artifacts. Kwak et al [8] defined punctate foci/microcalcifications as being <1 mm. Most authors define this feature on the basis of appearance alone (Fig. 5A).

- Macrocalcifications: When calcifications become large enough to result in posterior acoustic shadowing, they should be considered macrocalcifications. Macrocalcifications may be irregular in shape (Fig. 5B, online only).
- Peripheral calcifications: These calcifications occupy the periphery of the nodule. The calcification may not be completely continuous but generally involves the majority of the margin. Peripheral calcifications are often dense enough to obscure the central components of the nodule (Fig. 5C, online only).
- Comet-tail artifacts: A comet-tail artifact is a type of reverberation artifact. The deeper echoes become attenuated and are displayed as decreased width, resulting in a triangular shape. If an echogenic focus does not have this feature, a comet-tail artifact should not be described (Fig. 5D, online only).

Background and Significance.

- Echogenic foci have been associated with both benign and malignant lesions.
- Many authors have referred to all punctate echogenic foci in thyroid nodules simply as microcalcifications, but the majority of such foci are found in benign nodules, and therefore the term *microcalcification* is a misnomer [12]. The origins of punctate echogenic foci other than from true psammomatous microcalcifications of PTC are likely varied but, for example, have been shown to arise from the back walls of tiny unresolved cysts when seen in other organs such as the ovary or kidney. Although seen in both benign and malignant nodules, multiple studies have shown high specificity for

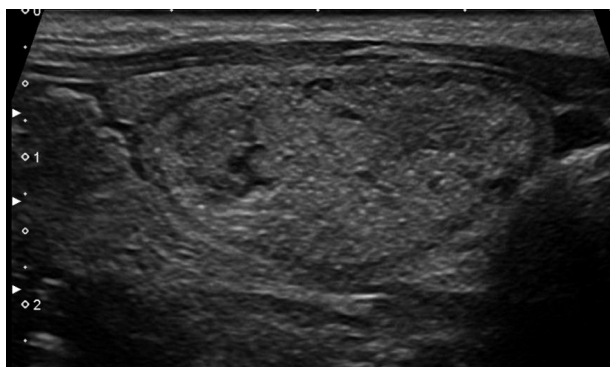


Fig 5A. Echogenic foci. Punctate echogenic foci: 44-year-old woman with 3.2-cm isoechoic smoothly marginated nodule. Note numerous punctate echogenic foci with no posterior acoustic artifacts. Diagnosis: colloid nodule (Bethesda 2). Figures 5B to 5D available online.

punctate echogenic foci in malignant nodules [15,19,30,31].

- Macrocalcifications are generally considered to have an association with increased risk for malignancy, perhaps slightly more than double the baseline risk [8,15,21].
- For peripheral calcifications, studies have been conflicting, with some demonstrating an increased association with malignancy and others not [12,22].
- Recently, authors have subclassified comet-tail artifacts into small and large types and found a prevalence of malignancy of 15% in nodules that had echogenic foci with small comet-tail artifacts [12]. Conversely, when considering large comet-tail artifacts in cystic or partially cystic nodules, multiple studies have shown a strong association with benignity [12,32,33].

Comment.

- When present, the type of echogenic focus encountered within a given nodule should be specified. If more than one type of echogenic focus is present in a single nodule, each should be enumerated. If none are present, this should be stated.

DISCUSSION

Ultrasound is the most commonly used imaging technique in the evaluation of thyroid nodules, and its use has increased the discovery of nodules greatly. With that in mind, and given that there are conflicting recommendations from several societies, the ACR sponsored this TIRADS project. In keeping with other similar projects, the eventual goal of TIRADS is to provide practitioners with evidence-based recommendations formulated upon defined sonographic features of a given nodule. This initial portion of our project was aimed at standardizing the diagnostic approach to thyroid nodules with regard to terminology.

A wide array of terms has been used to describe the characteristics of thyroid nodules. Closely examining the existing literature, we found that terms used to describe nodules are often poorly defined and inconsistently applied. Furthermore, multiple terms have often been used to describe the same feature. This has led to confusion as to when and how these terms should be applied and, in many cases, what they actually mean. Clearly, inconsistent reporting leads to confusion about recommendations for further management.

Our committee sought to use terms already in common use in the literature rather than inventing new ones. We sought to provide concise written definitions with illustrations that can be used as a guide for practitioners. Terms that were chosen demonstrated consistency with regard to performance in the diagnosis of thyroid cancer or to classifying a nodule as benign. Additionally, it was believed that features should be included that would be reproducible among various readers.

Although Doppler was considered as a potential category, the committee did not recommend its inclusion on the basis of inconsistent literature about its value in differentiating cancer from benign nodules. One might apply it technically (eg, to better define a subtle nodule), but this is not something that would influence the TIRADS classification.

Another problematic subject was nodule size. Again, there is no consistent information in the literature that equates increasing size to an increased incidence of cancer. On the other side of the size spectrum, the recent guidelines published by the ATA [26] state that only nodules greater than 1 cm should be evaluated, unless there are compelling circumstances, such as a lesion that bulges the thyroid capsule or has accompanying abnormal lymph nodes or nodules in patients with high-risk clinical factors. Reviewing the literature, we found that characteristics of thyroid nodules other than size are more closely associated with benign or malignant lesions, and we prefer that these form the basis for our standardized evaluation of thyroid nodules.

TAKE-HOME POINTS

- The goal of this project is to standardize terminology applied to thyroid nodules, such that all practitioners approach their evaluation in a similar fashion.
- The establishment of a lexicon is an essential initial step that provides a structured method for evaluation. The imager is directed to evaluate specific aspects of the nodule in an orderly fashion and is provided with a set of well-defined terms and features within each area of that evaluation.
- The aim is to decrease the variation seen in reporting of thyroid nodules in current practice. The ultimate goal is to develop guidelines for follow-up on the basis of statistics associated with the terms in the lexicon.

ONLINE FIGURES

Online figures can be found at: <http://dx.doi.org/10.1016/j.jacr.2015.07.011>.

REFERENCES

1. Ezzat S, Sarti DA, Cain DR, Braunstein GD. Thyroid incidentalomas. Prevalence by palpation and ultrasonography. *Arch Intern Med* 1994;154:1838-40.
2. Smith-Bindman R, Lebda P, Feldstein VA, et al. Risk of thyroid cancer based on thyroid ultrasound imaging characteristics: results of a population-based study. *JAMA Intern Med* 2013;173:1788-96.
3. Nam-Goong IS, Kim HY, Gong G, et al. Ultrasonography-guided fine-needle aspiration of thyroid incidentaloma: correlation with pathological findings. *Clin Endocrinol (Oxf)* 2004;60:21-8.
4. Ito Y, Miyauchi A, Inoue H, et al. An observational trial for papillary thyroid microcarcinoma in Japanese patients. *World J Surg* 2010;34:28-35.
5. Cooper DS, Doherty GM, Haugen BR, et al. Revised American Thyroid Association management guidelines for patients with thyroid nodules and differentiated thyroid cancer. *Thyroid* 2009;19:1167-214.
6. Frates MC, Benson CB, Charboneau JW, et al. Management of thyroid nodules detected at US: Society of Radiologists in Ultrasound consensus conference statement. *Radiology* 2005;237:794-800.
7. Cibas ES, Ali SZ. The Bethesda system for reporting thyroid cytopathology. *Am J Clin Pathol* 2009;132:658-65.
8. Kwak JY, Han KH, Yoon JH, et al. Thyroid Imaging Reporting and Data System for US features of nodules: a step in establishing better stratification of cancer risk. *Radiology* 2011;260:892-9.
9. Horvath E, Majlis S, Rossi R, et al. An ultrasonogram reporting system for thyroid nodules stratifying cancer risk for clinical management. *J Clin Endocrinol Metab* 2009;94:1748-51.
10. Park JY, Lee HJ, Jang HW, et al. A proposal for a thyroid imaging reporting end data system for ultrasound features of thyroid carcinoma. *Thyroid* 2009;19:1257-64.
11. Hoang JK, Langer JE, Middleton WD, et al. Managing incidental thyroid nodules detected on imaging: white paper of the ACR Incidental Thyroid Findings Committee. *J Am Coll Radiol* 2015;12:143-50.
12. Malhi H, Beland MD, Cen SY, Allgood E, Daley K, Martin SE, Cronan JJ, Grant EG. Echogenic foci in thyroid nodules: significance of posterior acoustic artifacts. *AJR Am J Roentgenol* 2014;203:1310-6.
13. Kim DW, Lee EJ, In HS, Kim SJ. Sonographic differentiation of partially cystic thyroid nodules: a prospective study. *AJNR Am J Neuroradiol* 2010;31:1961-6.
14. Henriksen TL, Reading CC, Charboneau JW, Donovan DJ, Sebo TJ, Hay ID. Cystic change in thyroid carcinoma: prevalence and estimated volume in 360 carcinomas. *J Clinical Ultrasound* 2010;38:361-6.
15. Moon WJ, Jung SL, Lee JH, Na DG, Baek JH, et al. Benign and malignant thyroid nodules: US differentiation-multicenter retrospective study. *Radiology* 2008;247:762-70.
16. Bonavita JA, Mayo J, Babb J, Bennett G, Oweity T, Macari M, Yee J. Pattern recognition of benign nodules at ultrasound of the thyroid: which nodules can be left alone? *AJR Am J Roentgenol* 2009;193:207-13.
17. Ahn SS, Kim E-K, Kang DR, Lim S-K, Kwak JY, Kim MJ. Biopsy of thyroid nodules: comparison of three sets of guidelines. *AJR Am J Roentgenol* 2010;194:31-7.
18. Frates MC, Benson CB, Doubilet PM, et al. Prevalence and distribution of carcinoma in patients with solitary and multiple thyroid nodules on sonography. *J Clin Endocrinol Metab* 2006;91:3411-7.
19. Papini E, Guglielmi R, Bianchini A, et al. Risk of malignancy in nonpalpable thyroid nodules: predictive value of ultrasound and color-Doppler features. *J Clin Endocrinol Metab* 2002;87:1941-6.
20. Moon HJ, Kwak JY, Kim EK, Kim MJ. A taller-than-wide shape in thyroid nodules in transverse and longitudinal ultrasonographic

- planes and the prediction of malignancy. *Thyroid* 2011;21:1249-53.
21. Moon HJ, Sung JM, Kim EK, Yoon JH, Youk JH, Kwak JY. Diagnostic performance of gray-scale US and elastography in solid thyroid nodules. *Radiology* 2012;262:1002-13.
 22. Kim HG, Moon HJ, Kwak JY, Kim EK. Diagnostic accuracy of the ultrasonographic features for subcentimeter thyroid nodules suggested by the revised American Thyroid Association guidelines. *Thyroid* 2013;23:1583-90.
 23. Chen SP, Hu YP, Chen B. Taller-than-wide sign for predicting thyroid microcarcinoma: comparison and combination of two ultrasonographic planes. *Ultrasound Med Biol* 2014;40:2004-11.
 24. Harach HR, Franssila KO, Wassenius VM. Occult papillary carcinoma of the thyroid. A "normal" finding in Finland. A systematic autopsy study. *Cancer* 1985;56:531-8.
 25. Kamran SC, Marqusee E, Kim MI, et al. Thyroid nodule size and prediction of cancer. *J Clin Endocrinol Metab* 2013;98:564-70.
 26. Haugen BR, Alexander EK, Bible KC, et al. 2015 American Thyroid Association management guidelines for patients with thyroid nodules and differentiated thyroid cancer. *Thyroid* 2015 Oct 14 [Epub ahead of print].
 27. Chan BK, Desser TS, McDougall IR, et al. Common and uncommon sonographic features of papillary thyroid carcinoma. *J Ultrasound Med* 2003;22:1083-90.
 28. Kim EK, Park CS, Chung WY, et al. New sonographic criteria for recommending fine-needle aspiration biopsy of nonpalpable solid nodules of the thyroid. *AJR Am J Roentgenol* 2002;178:687-91.
 29. Hoang JK, Lee WK, Lee M, et al. US features of thyroid malignancy: pearls and pitfalls. *Radiographics* 2007;27:847-60.
 30. Miofo B, Takoeto EO, Tambe J, Blanc F, Fotsin JG. Reliability of Thyroid Imaging Reporting and Data System (TIRADS) classification in differentiating benign from malignant thyroid nodules. *Open J Radiol* 2013;3:103-7.
 31. Iannuccilli JD, Cronan JJ, Monchik JM. Risk of malignancy as assessed by sonographic criteria: the need for biopsy. *J Ultrasound Med* 2004;23:1455-64.
 32. Ahuja A, Chick W, King W, Metreweli C. Clinical significance of the comet-tail artifact in thyroid ultrasound. *J Clinical Ultrasound* 1996;24:129-33.
 33. Beland MD, Kwon L, Delellis RA, Cronan JJ, Grant EG. Non-shadowing echogenic foci in thyroid nodules are certain appearances enough to avoid thyroid biopsy? *J Ultrasound Med* 2011;30:753-60.