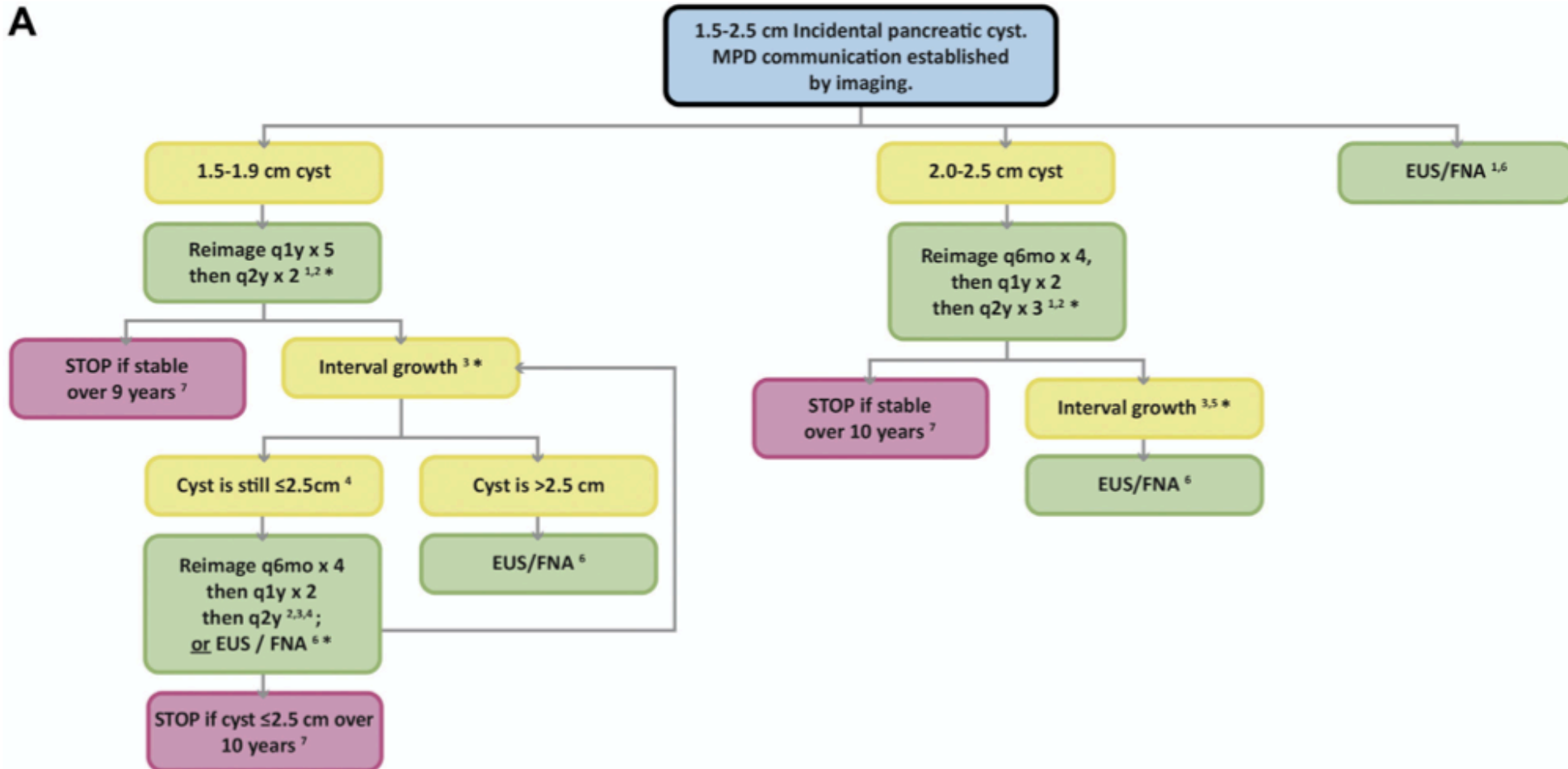


A



LEGEND

1 EUS/FNA can be performed instead of follow-up imaging: 1) at detection; or 2) after entry into chart (from Figure 1). In general, EUS/FNA merits stronger consideration for larger or faster-growing cysts relative to smaller or slower-growing cysts.

2 Imaging follow-up with contrast-enhanced MRI or pancreas protocol CT.

3 Growth defined as 20% increase in longest axis diameter, as depicted on either axial or coronal image. No growth = stable.

4 Following growth, imaging follow-up or EUS/FNA may be performed. In general, EUS/FNA merits stronger consideration for larger or faster-growing cysts relative to smaller or slower-growing cysts.

5 Definable growth of any cyst ≥ 2 cm at detection (or at entry from Figure 1) will result in a cyst that is at minimum 2.4cm; for such cysts, EUS/FNA is advised.

6 After EUS/FNA, further work-up is result-dependent (see Figure 2B).

7 If the patient reaches 80 years before the end of follow-up, follow-up should generally stop. If the patient is close to – but not yet – 80 years when the cyst is first detected, then when the patient reaches 80 years, Figure 4 can be used to guide further management.

*Appearance of any mural nodule, wall thickening, dilation of MPD ≥ 7 mm, or extrahepatic biliary obstruction/jaundice should prompt immediate EUS/FNA and surgical evaluation regardless of size or amount of growth.